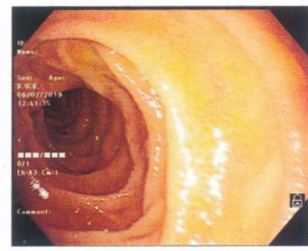
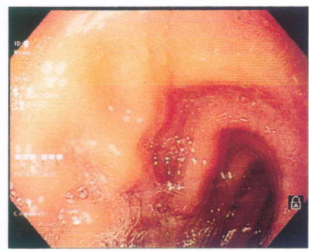
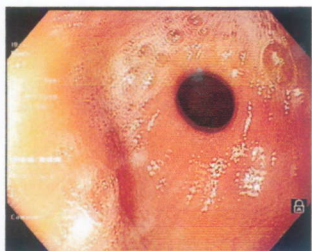
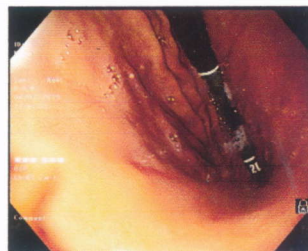
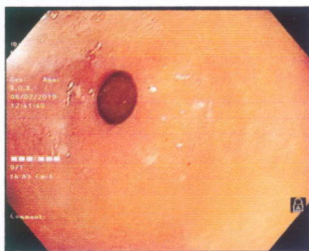
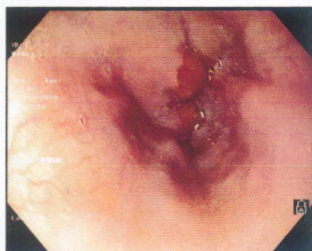


Patient ID: 2019020020
Name: Mr. BADAN BARMAN
Age: 37 Y
Sex: M
Date: 06-Feb-2019

Ref By: SELF
Study: UGI Endoscopy
Examined By: Dr. Bhaskar Jyoti Baruah DM



UGI ENDOSCOPY REPORT

SEEN UPTO DUODENUM.

OESOPHAGUS: Normal Mucosa

GE JUNCTION: Normal Mucosa

STOMACH : Multiple clea base ulcers seen at antrum.

DUODENUM:

PART - I : Normal Mucosa

PART - II : Normal Mucosa

IMPRESSION: Antral ulcers.

Dr. Bhaskar Jyoti Baruah
DM